

Orthopädie Heidelberg

Surgical Aspects and Techniques for Bone and Soft-Tissue Sarcomas

B. Lehner, V. Ewerbeck

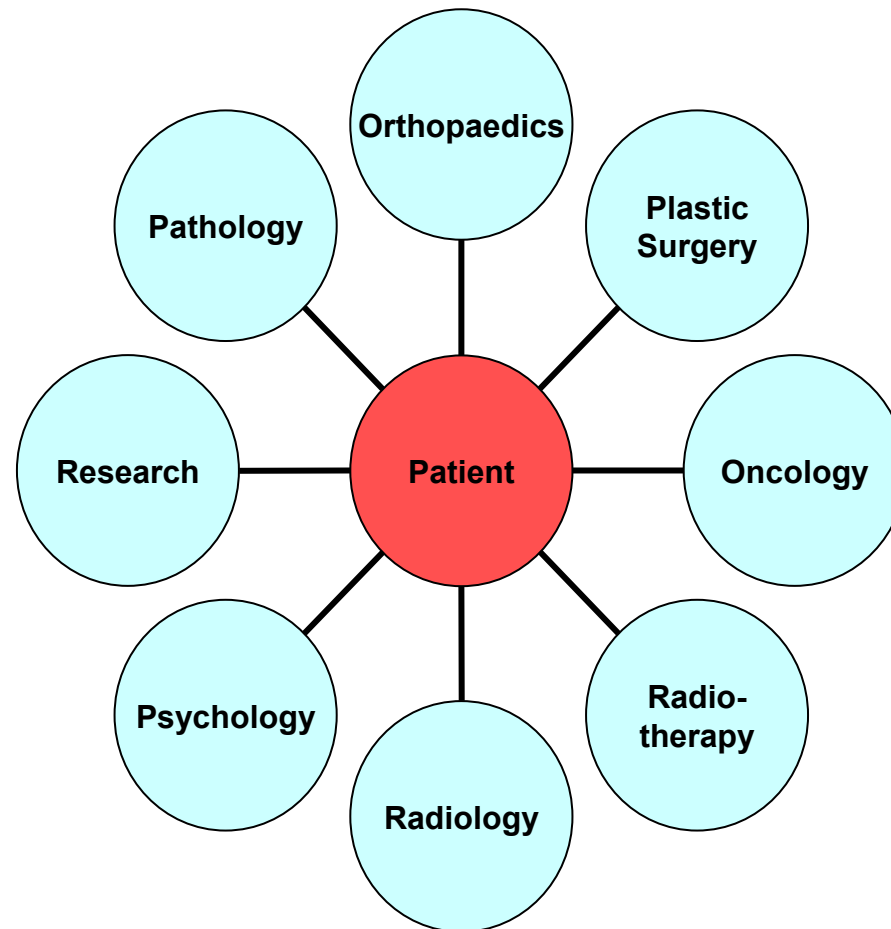
Orthopedic university clinic Heidelberg
Director: Prof. Dr. V. Ewerbeck



Surgical treatment of sarcomas

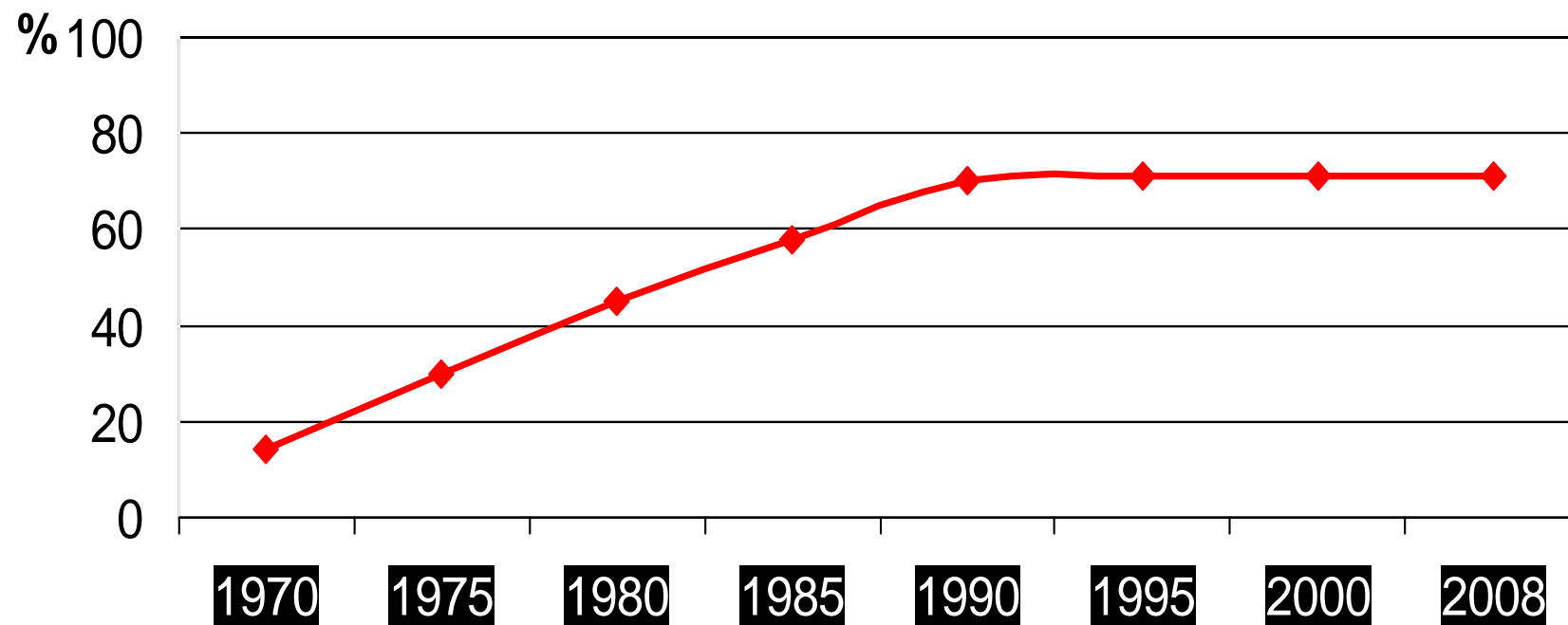


Orthopädie Heidelberg





Survival rate Osteosarcoma (COSS)





5-Year-Survival of Soft tissue sarcoma

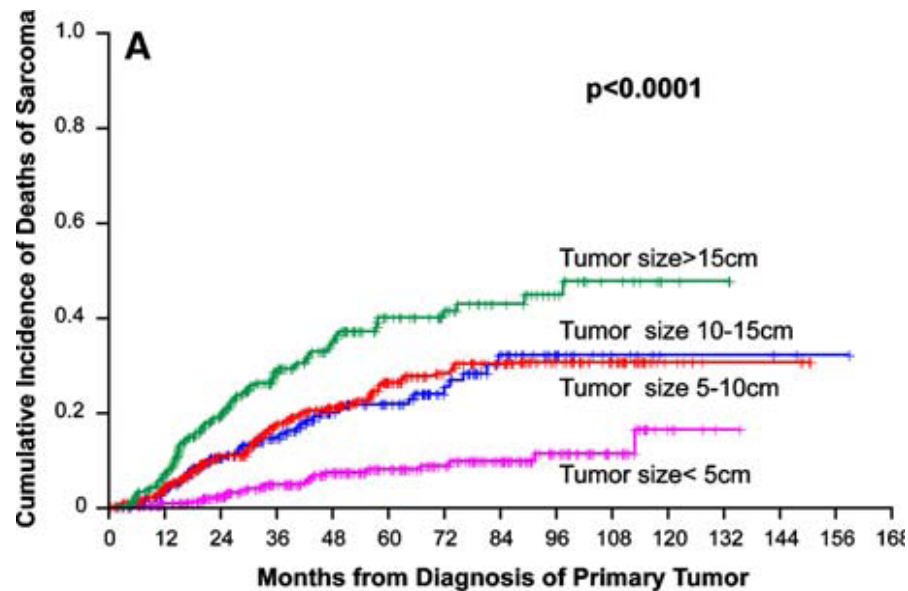
- High-grade Sarcoma: 62%
 - Low-grade Sarcoma: 87%
- dependent of tumour stage



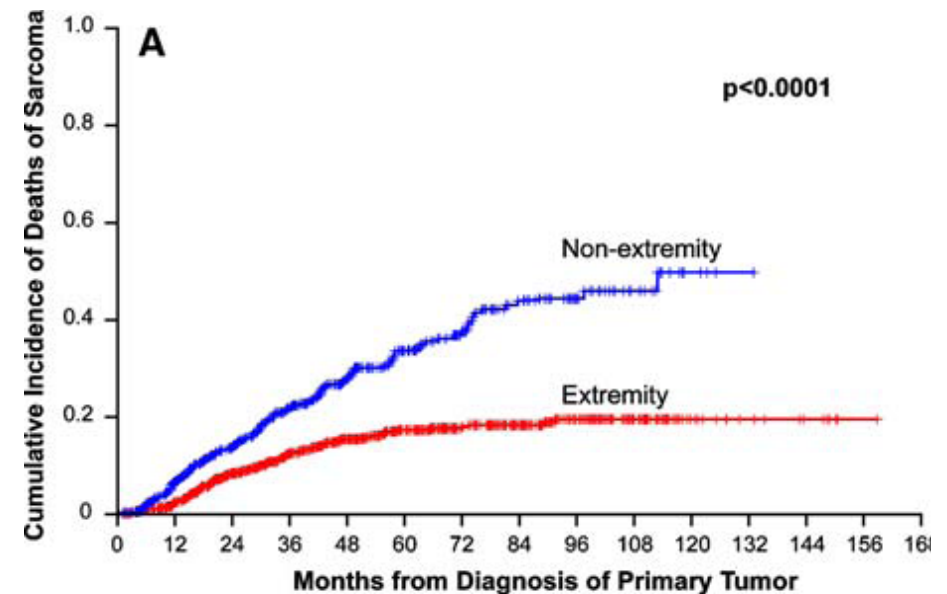
Surgical treatment of sarcomas



Orthopädie Heidelberg



survival and tumor size



survival and tumor localisation

Lahat et al, Ann Surg Oncol, 2008



Adjuvant Chemotherapy in the treatment of soft tissue sarcomas

- Role of neoadjuvant or adjuvant chemotherapy still unclear
- No improvement in the overall survival
- But: In cases of high-risk sarcomas ?
- Effectiveness of chemotherapy is tumour entity-dependent (chemosensitive: Synovial sarcoma)



Adjuvant Radiation therapy in the treatment of Soft tissue sarcomas

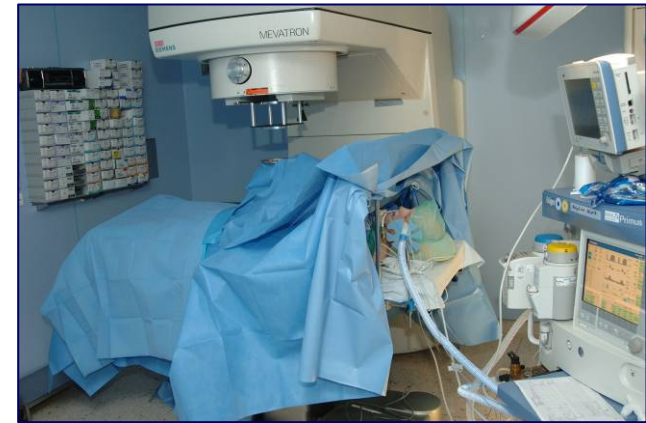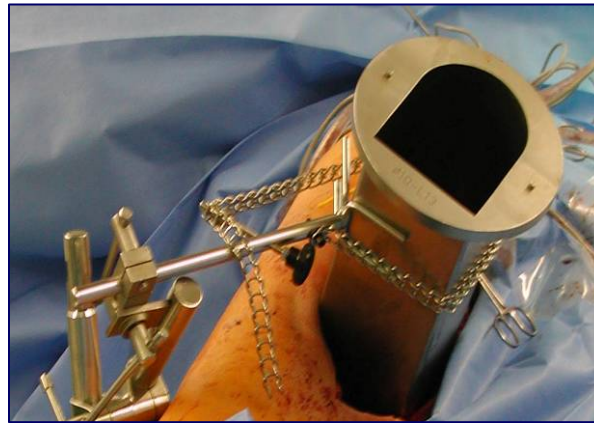
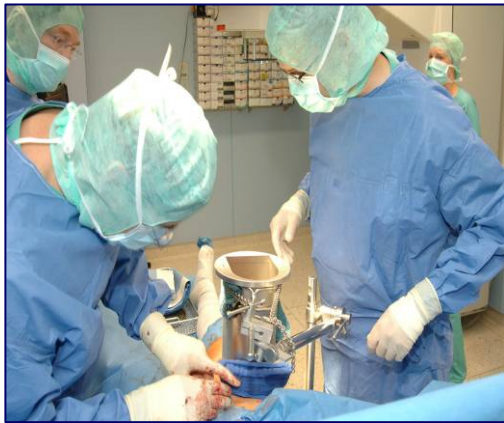- Significant improvement in local tumour control
- But: failed to improve overall survival
- Recommendation for high grade tumours with marginal resection and deep tumours with an extension of ≥ 5 cm



Surgical treatment of sarcomas



Intraoperative electron boost radiotherapy (IOERT)



Median dose 15 Gy + postoperative external beam radiotherapy 43 Gy



Intraoperative electron boost radiotherapy (IOERT)

n = 86 Orthopedic clinic Heidelberg

- 5y overall survival 62%
depends on resection status, grading
- 5y local control 77%
depends on resection status, IOERT dose
- Extremity salvage until death 88%
- Enneking score 78%
- Fracture rate 5%



The complete resection of the primary tumour is pivotal for the oncological outcome



Surgical treatment of sarcomas



Surgical goal for soft tissue sarcomas

- en bloc resection beyond the reactive area of the compartment
- wide resection margins
- 2-3 cm safety margins

Surgical options

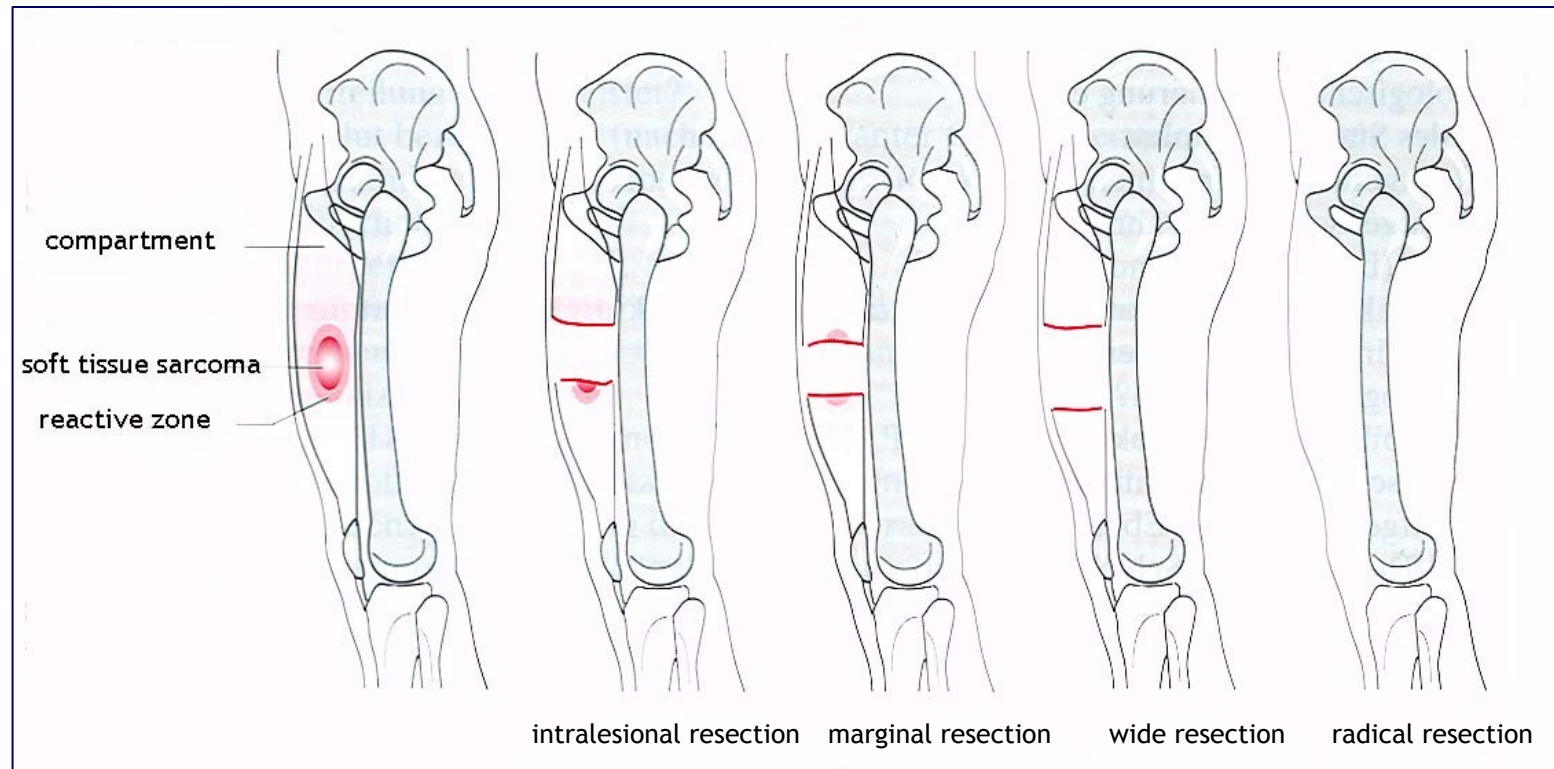
- reconstructive surgery
 - vascular and soft tissue graft, plastic surgery
- ablative surgery



Surgical treatment of sarcomas

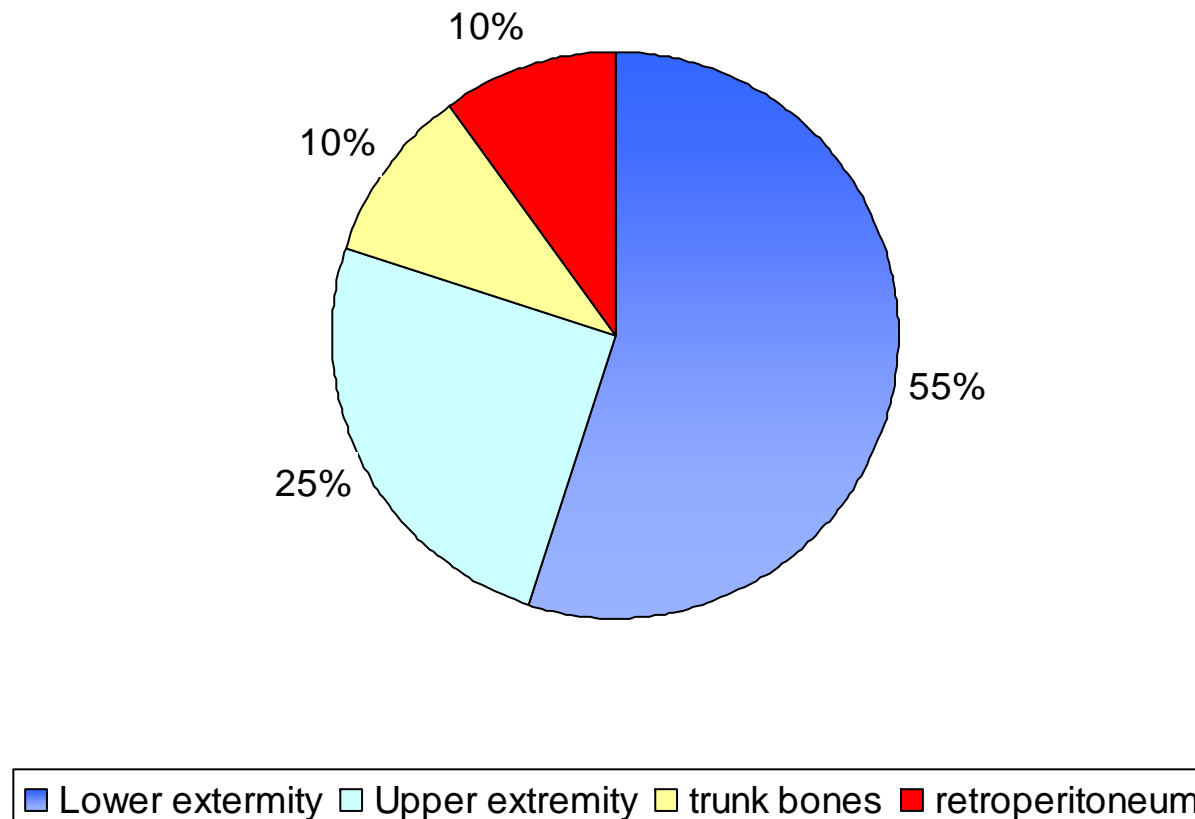


Orthopädie Heidelberg

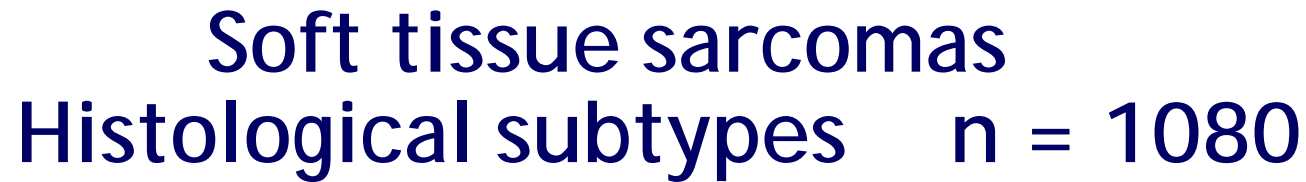
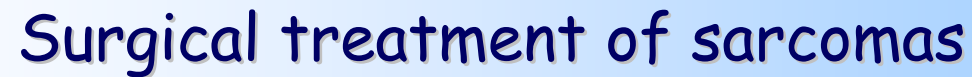


Tumour location soft tissue sarcomas



Fletcher et al, WHO classification of tumours, 2002



- Liposarcomas 33 %
- MFH 24 %
- Leiomyosarcomas 16 %
- Synovialsarcomas 12 %
- MPNST 8 %
- Rhabdomyosarcomas 2 %
- NOS 5 %

Dept. of Pathology, University Heidelberg, 1991-2008



Surgical goal for bone sarcomas

- ➔ wide tumour resection
 - 3 cm safety margins
 - adequate soft tissue cover of the tumour

Surgical options

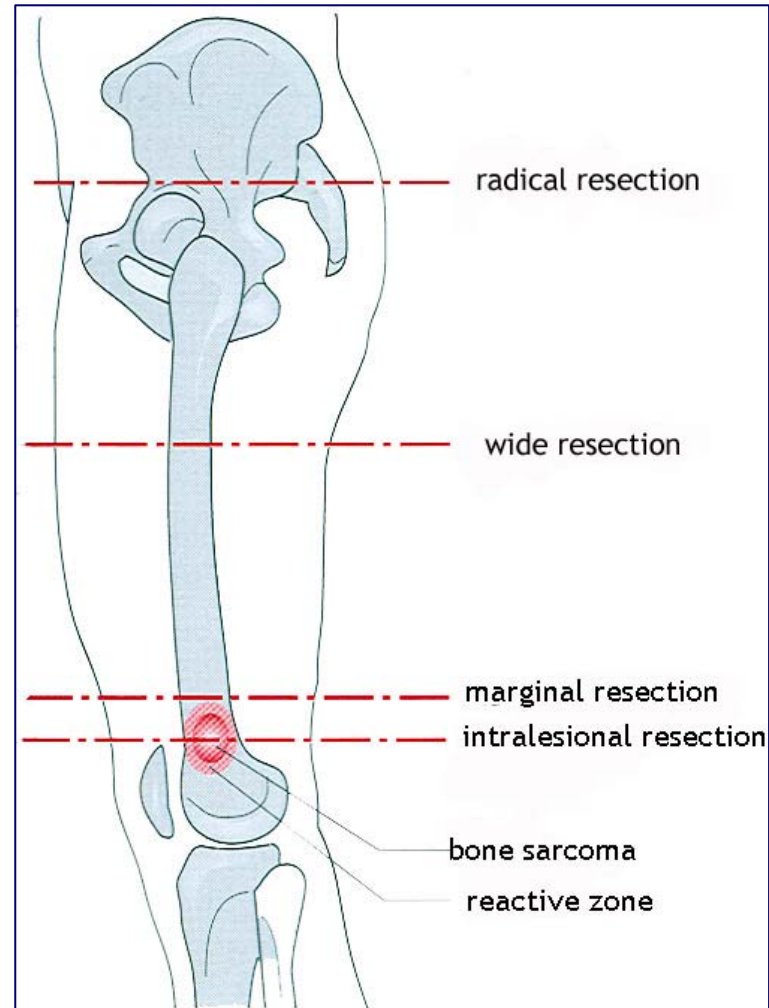
- ➔ reconstructive surgery
- ➔ ablative surgery



Surgical treatment of sarcomas

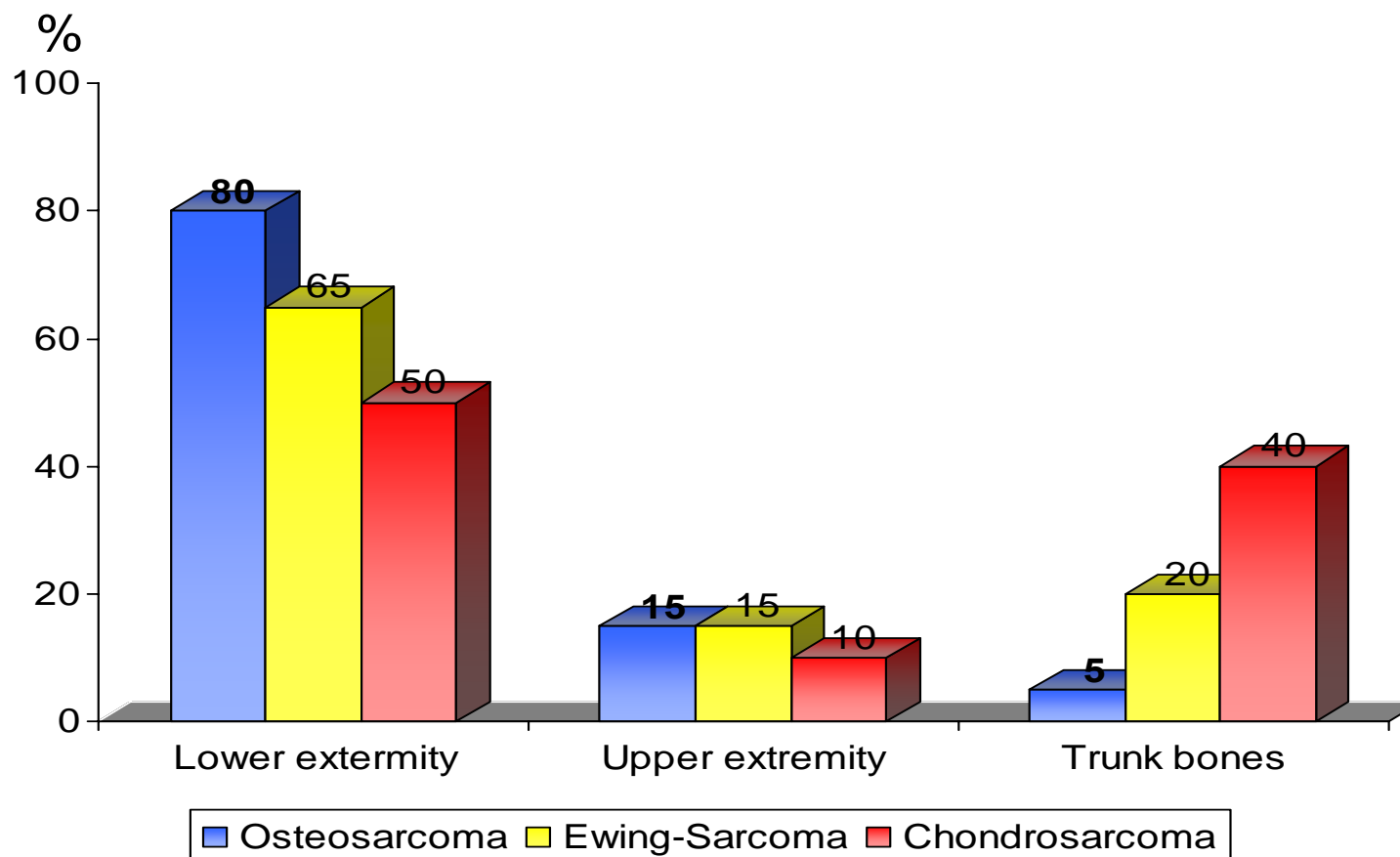


Orthopädie Heidelberg





Tumour location bone sarcomas





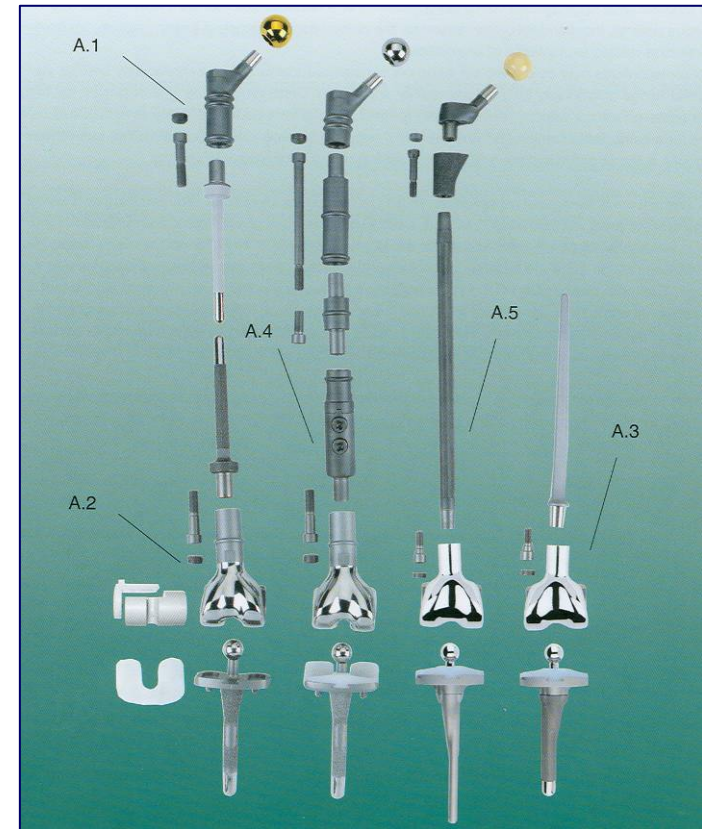
Reconstructive surgery

- Modular endoprosthesis system
 - Autografts (Fibula, cancellous bone)
 - Allografts
- } Biological Reconstruction



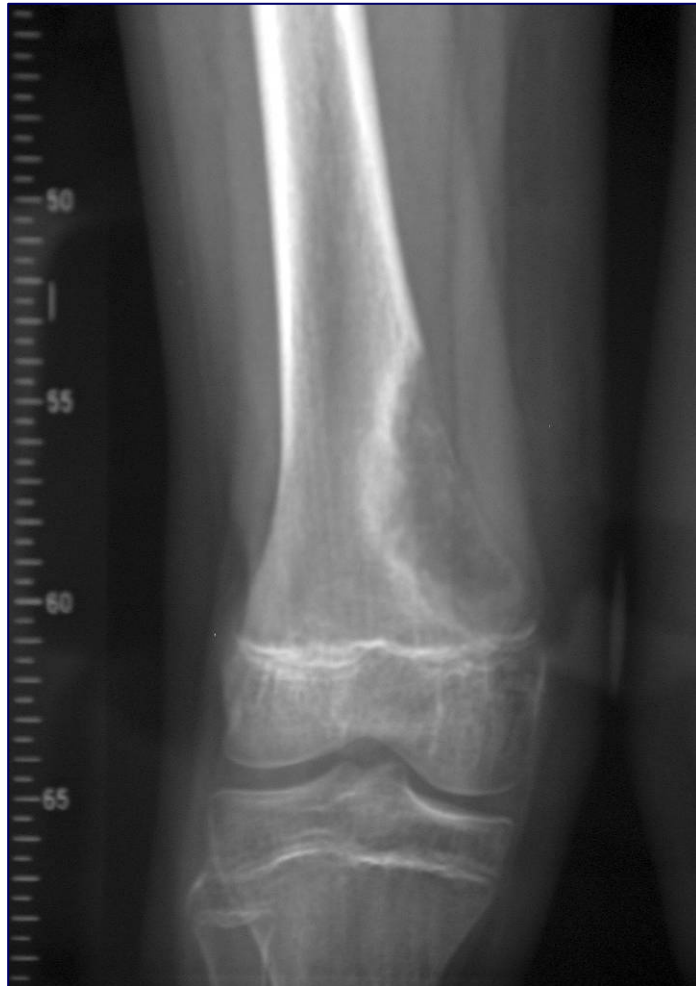Modular tumour endoprosthesis system (MUTARS)

- Maximum load capacity (lower extremity!)
- Reconstruction of major osseous defects with joint involvement





Surgical treatment of sarcomas




High Grade osteoblastic
Osteosarcoma distal femur

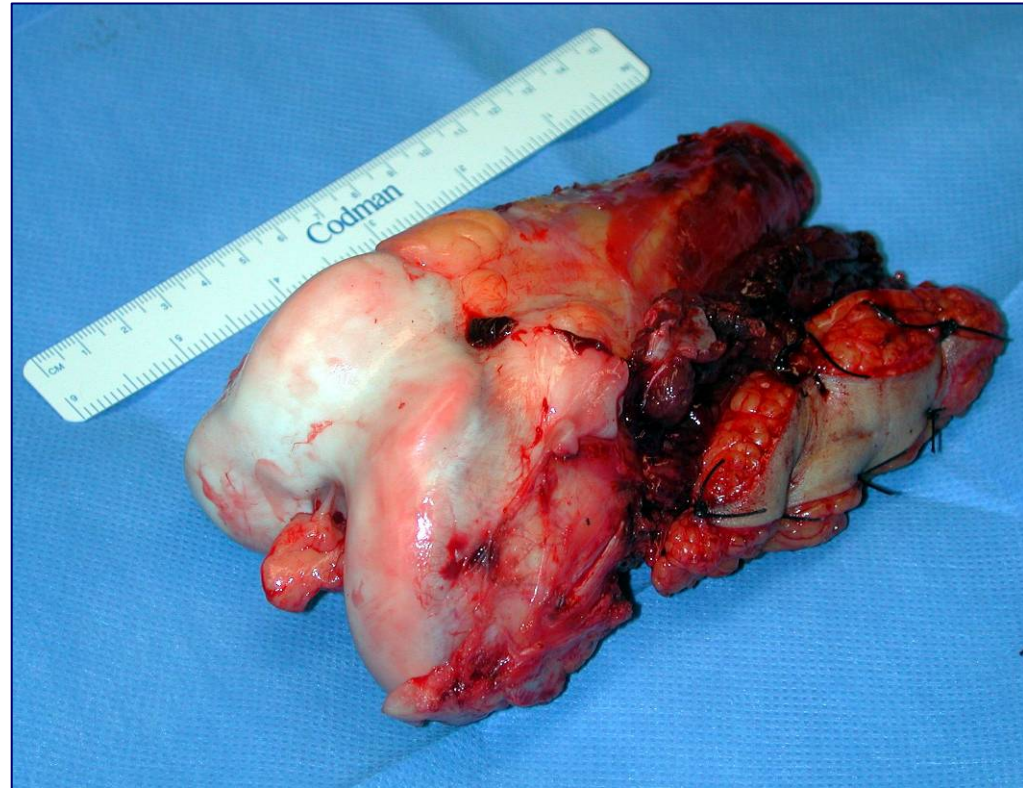
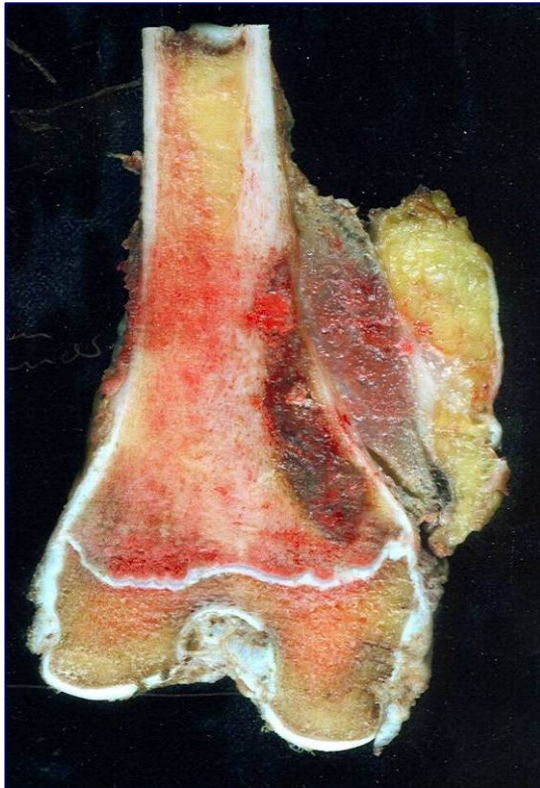16y old boy



Surgical treatment of sarcomas




Orthopädie Heidelberg

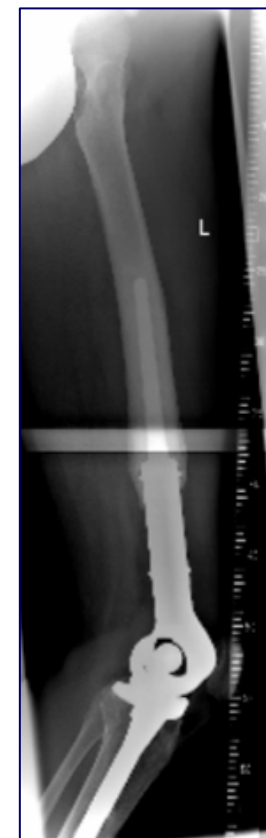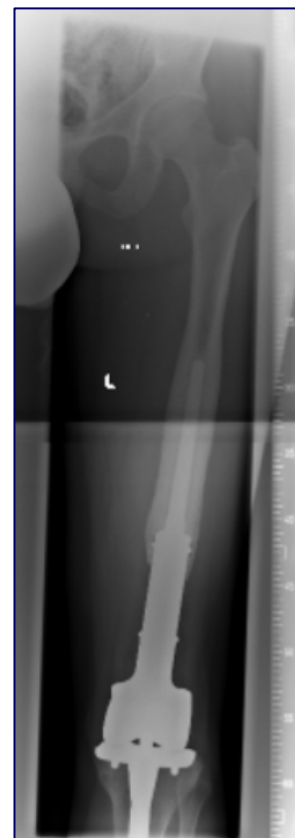
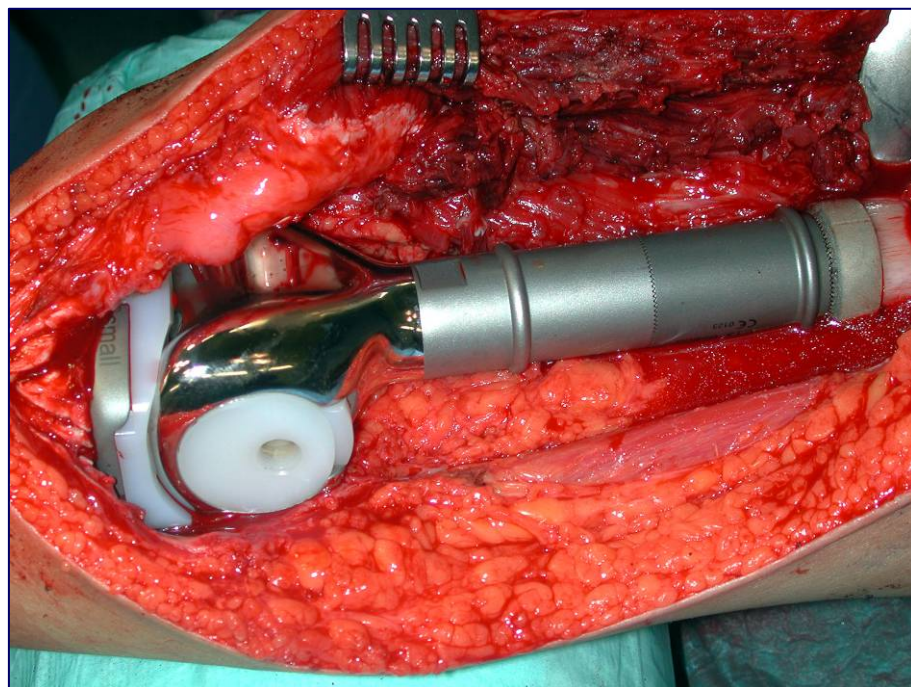




Surgical treatment of sarcomas



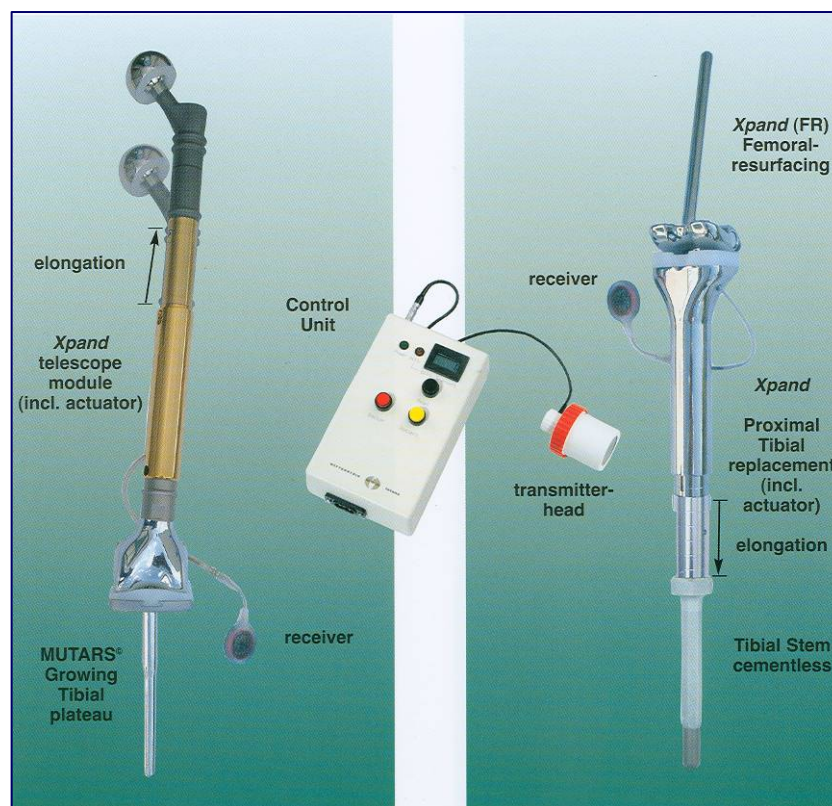
Orthopädie Heidelberg





Surgical treatment of sarcomas

Extendable prosthesis for children (growing prosthesis)





Biological reconstruction

Reconstruction of physiological
conditions by using autologous
substances



Autologous bone

pros

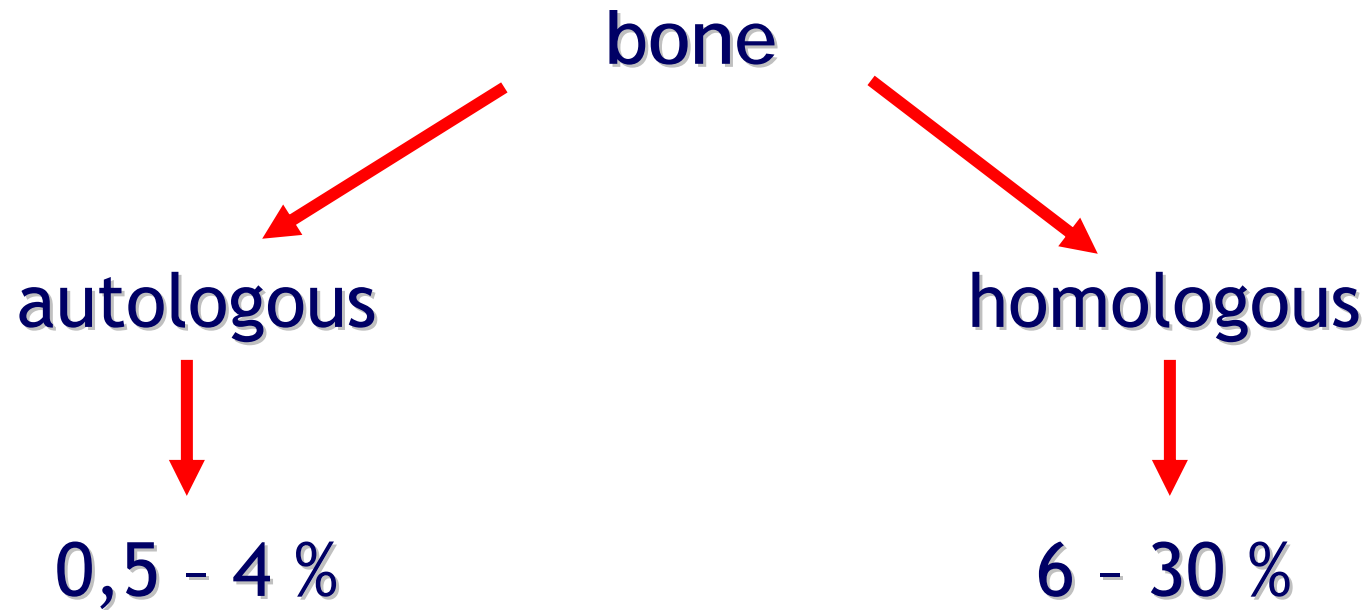
- facilitated complication management
- lower infection rate
- lower pseudoarthrosis rate
- higher adaptability
- no logistics (transportation, storage etc.)

contras

- limited availability
- insufficient load bearing capacity
- no joint replacement



Infection rate





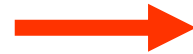Autologous bone

- Clavicula pro humero
- Fibula
 - with / without caput fibulae
 - with / without vascular pedicle graft
- cancellous bone (pelvis, ribs, radius, tibia)

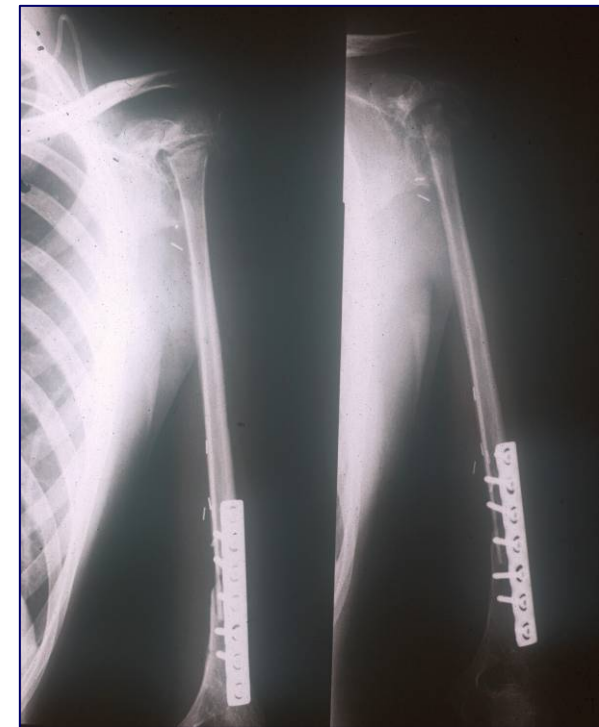
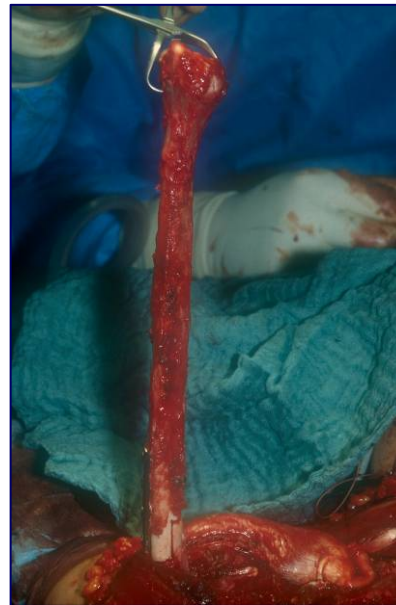
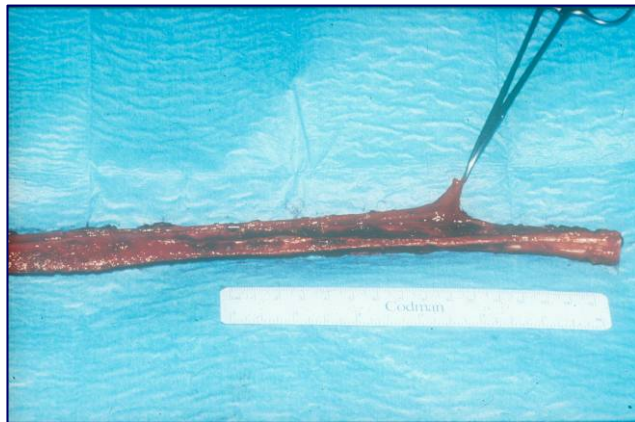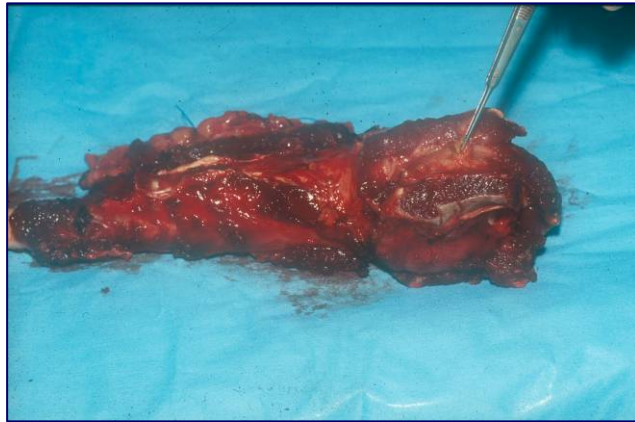


Surgical treatment of sarcomas

13 year old female
Osteosarcoma proximal humerus

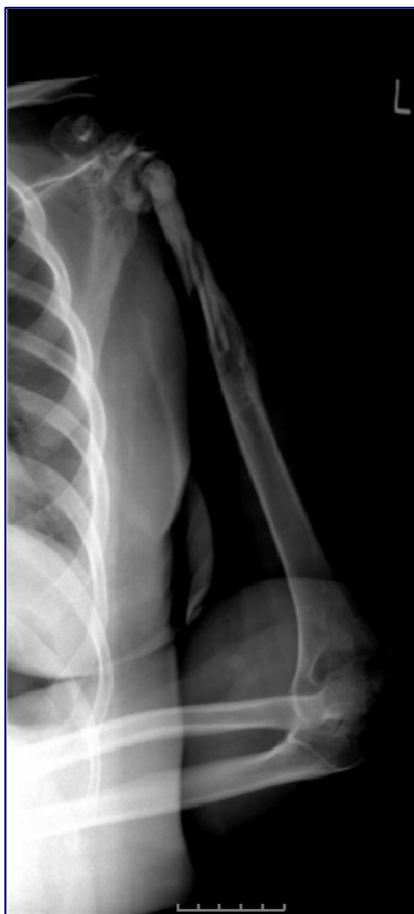

Reconstruction with
vascular pedicle fibula graft

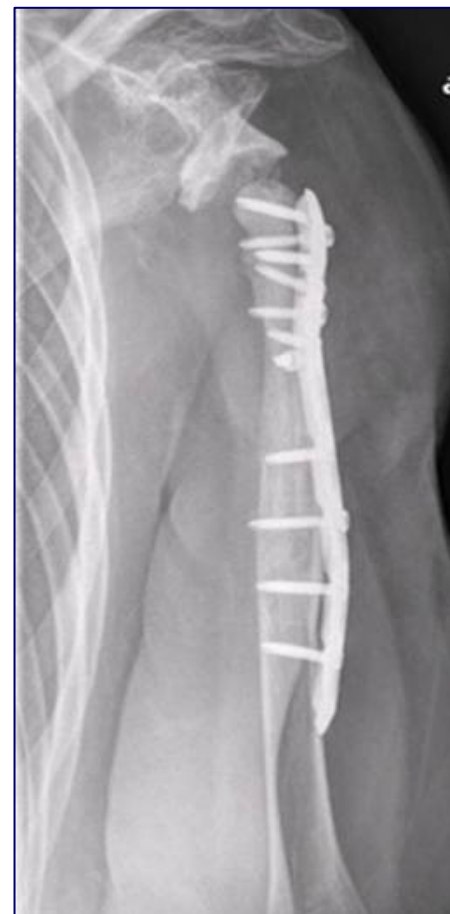



Surgical treatment of sarcomas



Fracture of fibula graft during
kick-boxing
14y following resection of
Ewing sarcoma



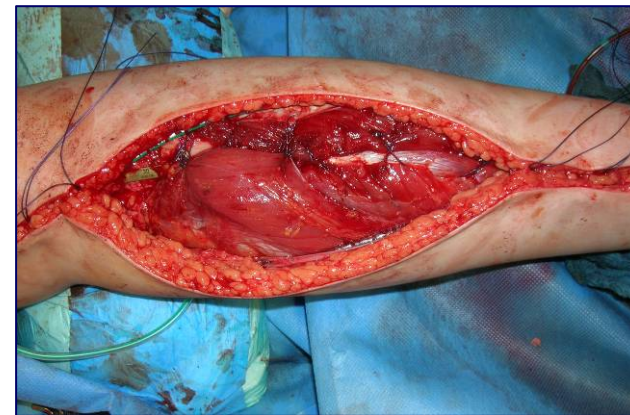
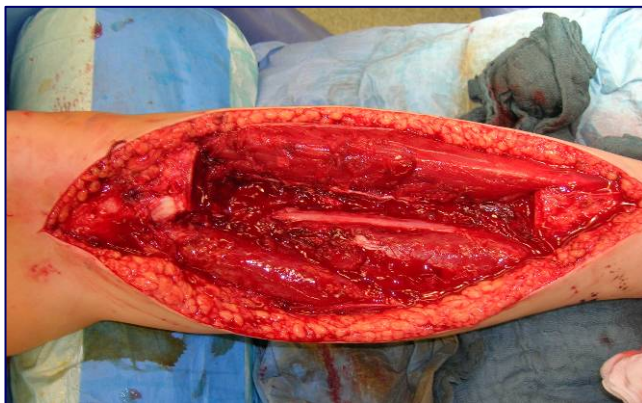
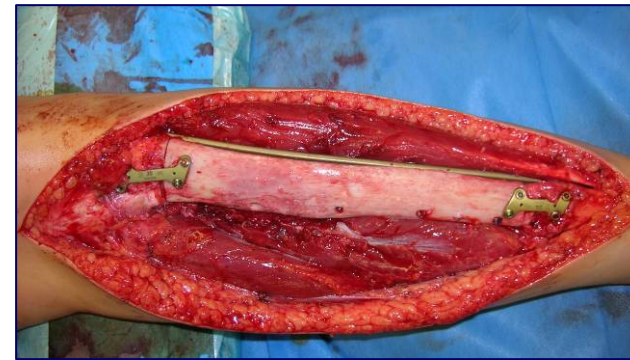
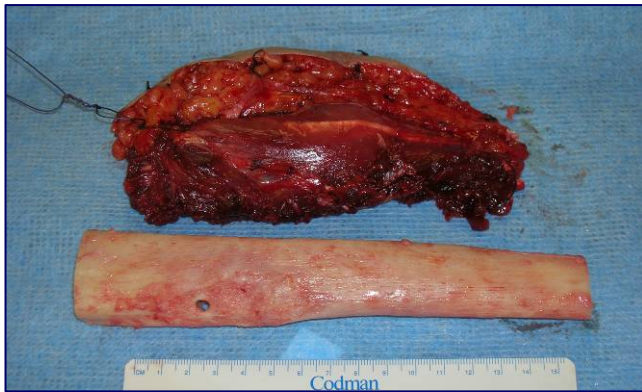
Surgical treatment of sarcomas

30 year old female
Ewing sarcoma tibia



Reconstruction with
intraoperative extracorporeal
lethal irradiated autologous tibia

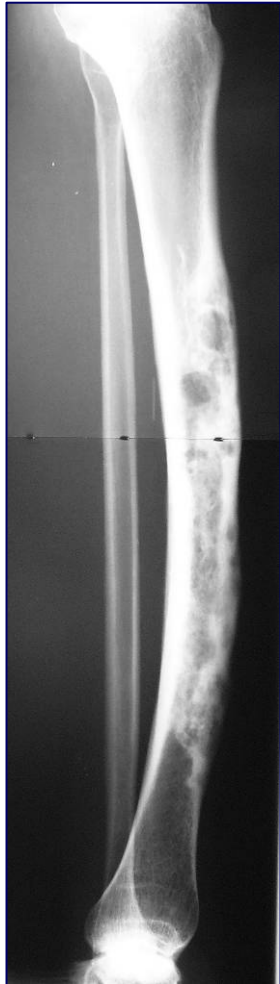



Surgical treatment of sarcomas

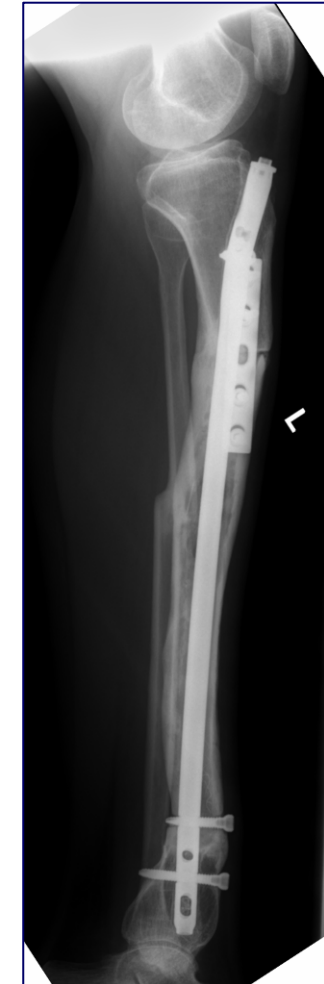
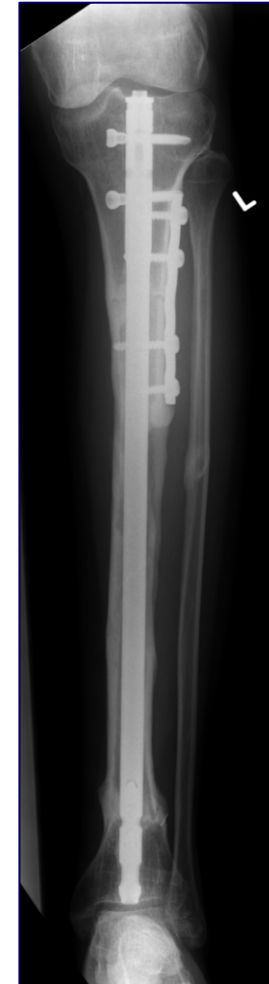
Orthopädie Heidelberg



2005

Ingrowth of tibia following
reconstruction with
intraoperative extracorporeal
lethal irradiated autologous tibia
50y old patient with Adamantinoma



2009

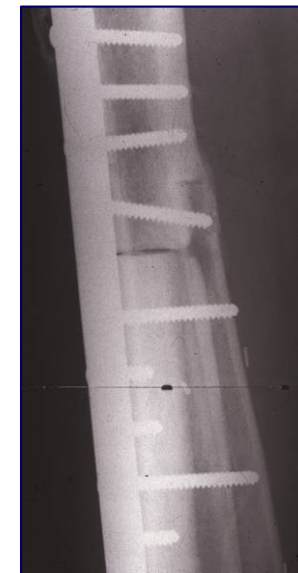
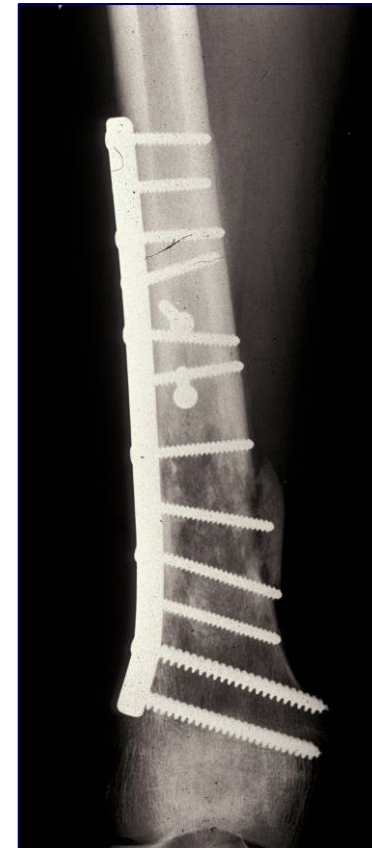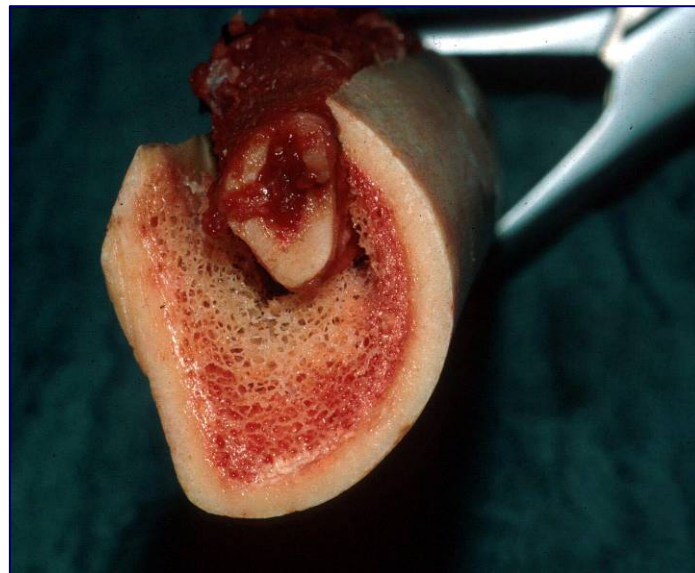
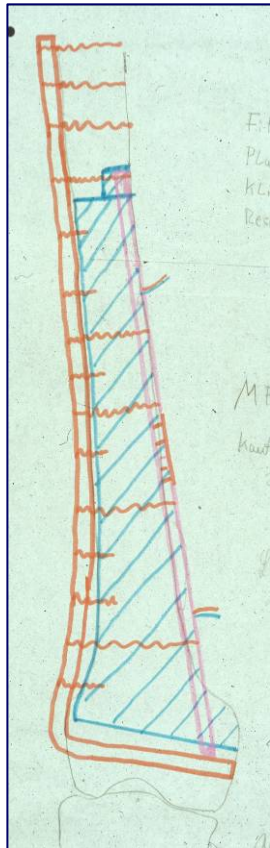


Surgical treatment of sarcomas



Orthopädie Heidelberg

Combined vascularized fibula (autograft) and allograft shell "mantle transplant"





Complication rate

Reconstructive surgery

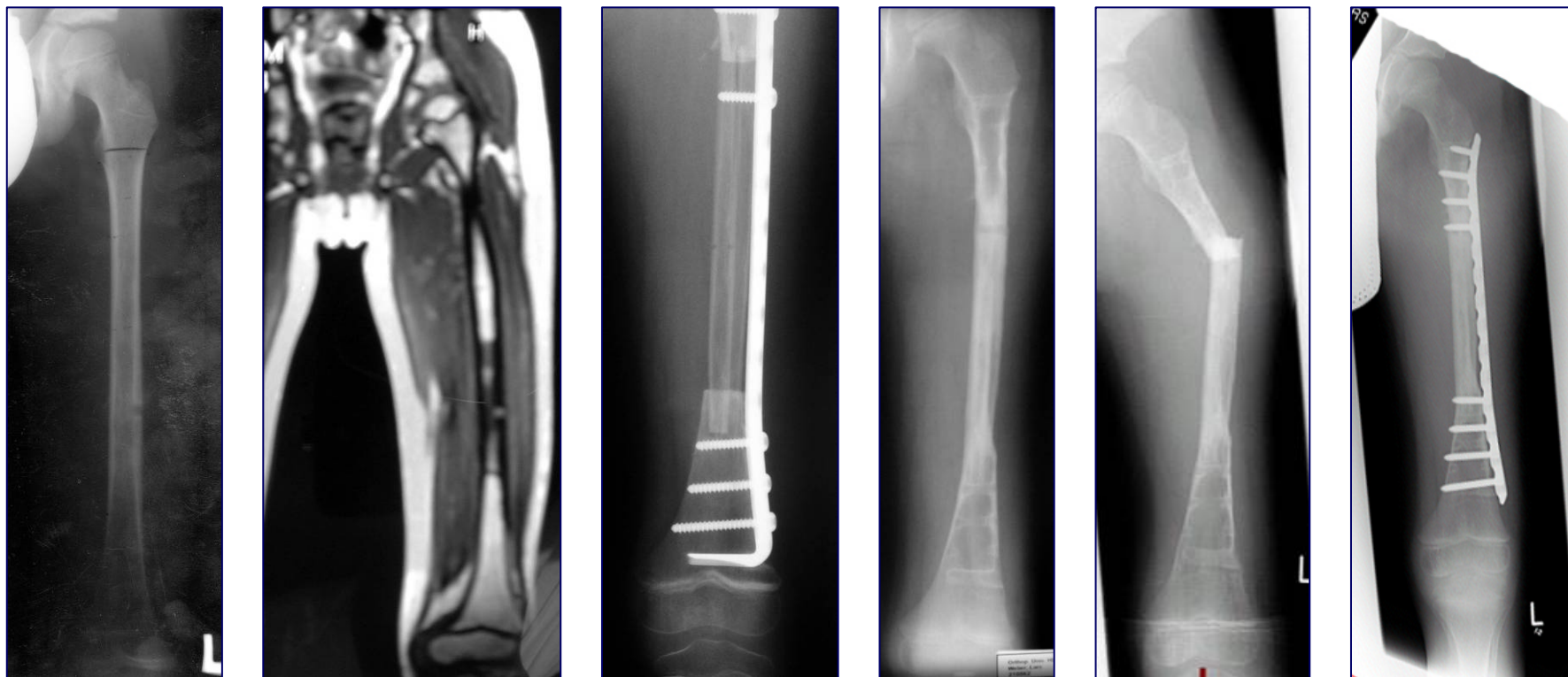


34-60 %

- Infection
- Aseptic loosening
- Implant failure
- Fracture



Complication of biologic reconstruction



Fracture of fibula autograft following resection of Ewing sarcoma

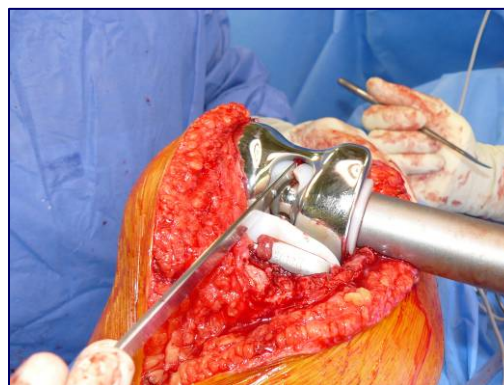


Complication rate MUTARS (n=120)

Complication	≥ 5 years	total
Aseptic loosening	11/63 (17 %)	13/120 (11 %)
Implant failure	14/63 (22 %)	18/120 (15 %)
Septic loosening	7/63 (11 %)	11/120 (9 %)



Implant failure

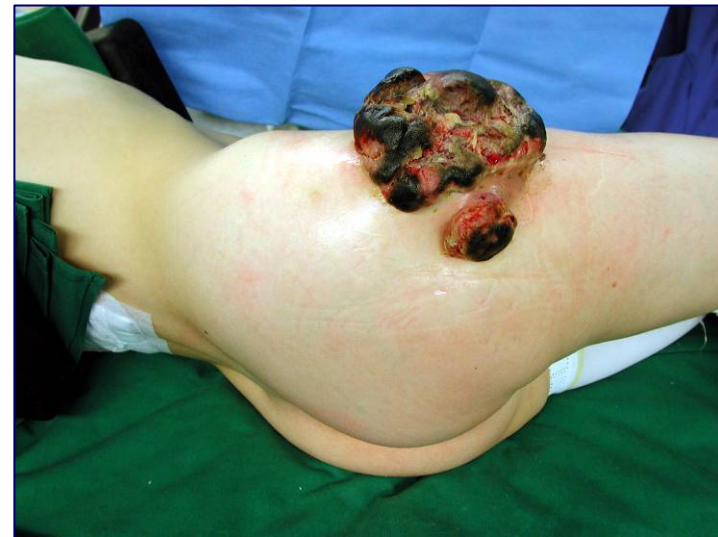

Breakage of locking mechanism



Indication for ablative therapy

- Infiltration of nerve and vascular bundle
- Tumour size
- Recurring tumour
- Palliation



30y old patient with MFH

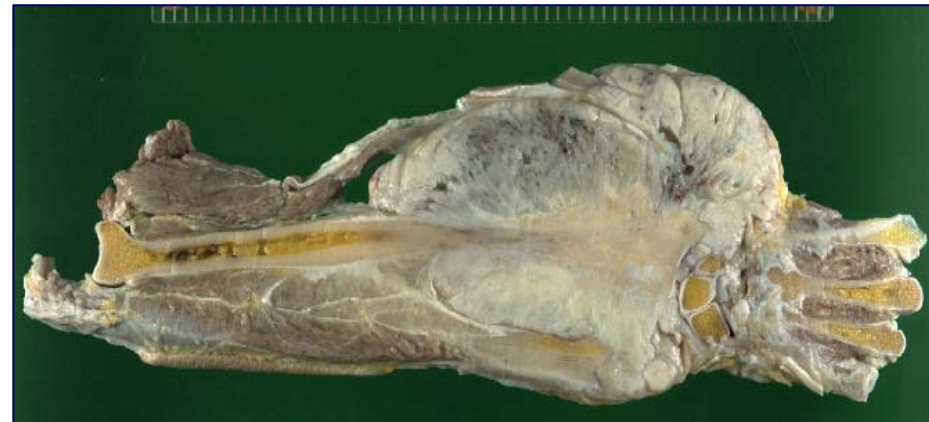
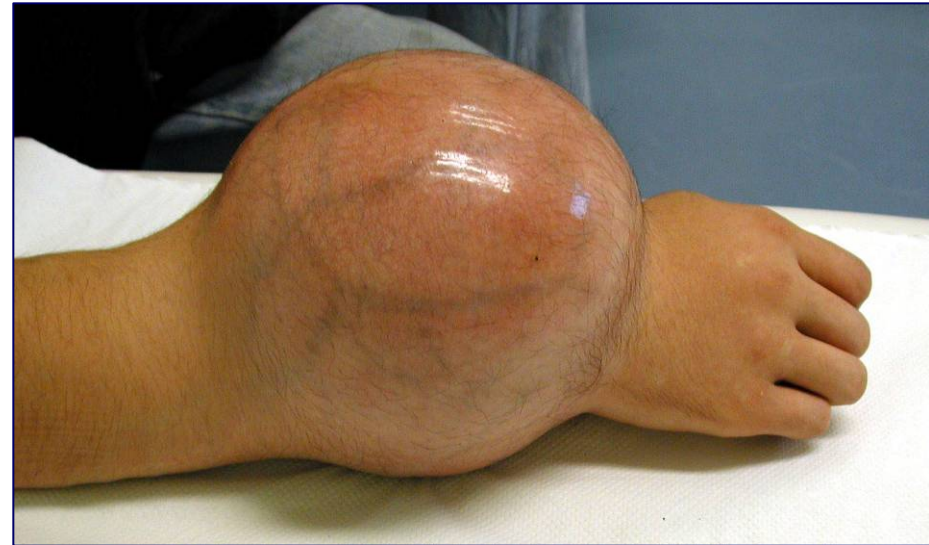
Surgical treatment of sarcomas

Osteosarcoma
distal radius
20 year old male



Ablative therapy





Disadvantage of amputation?

- Function of amputation (n = 16) 65 %
- Function of reconstructive surgery (n = 50) 77 %
- Quality of life, life satisfaction
 - no significant difference
 - dependent on tumour location



Surgical treatment of sarcomas



Orthopädie Heidelberg



New developments
of exoprostheses





Complication rate

Amputation

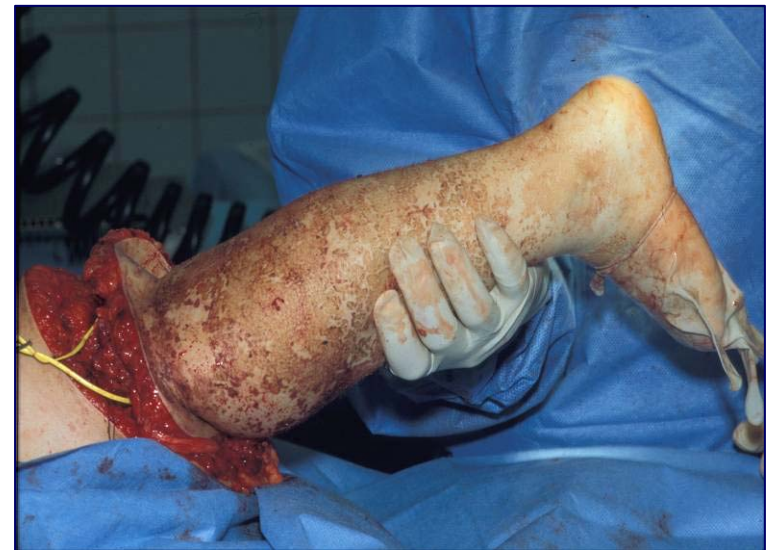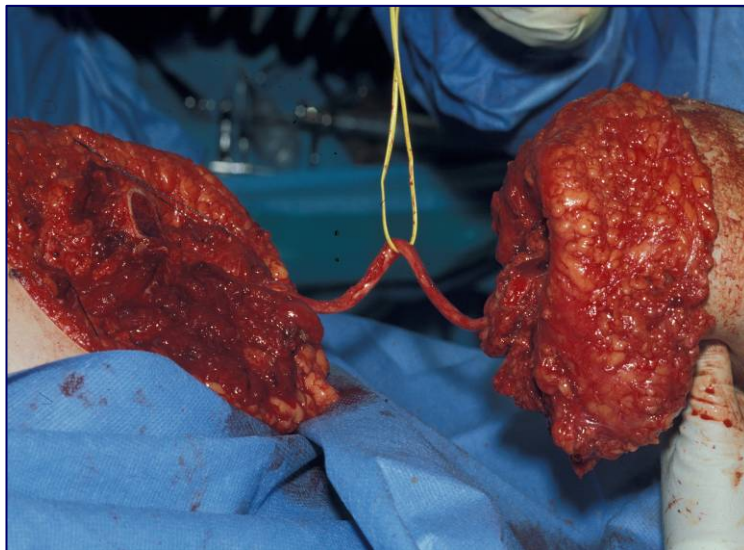
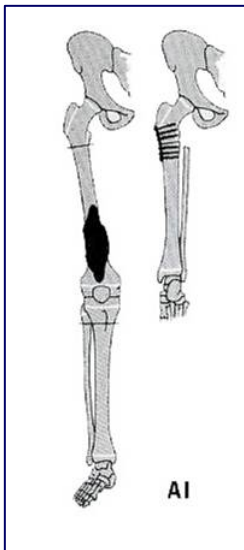


3 - 40 %

- Phantom pain
- Soft tissue necrosis




Special ablative surgery: rotation-plasty



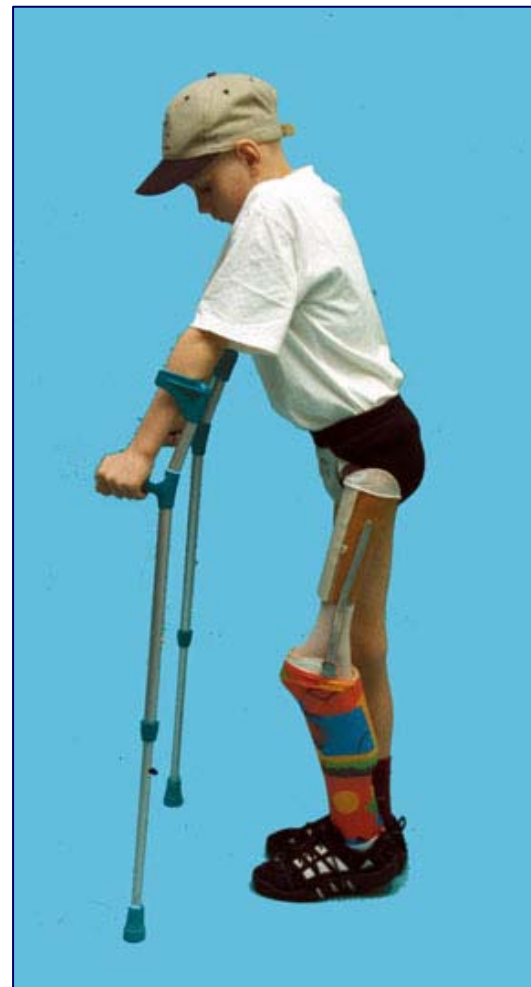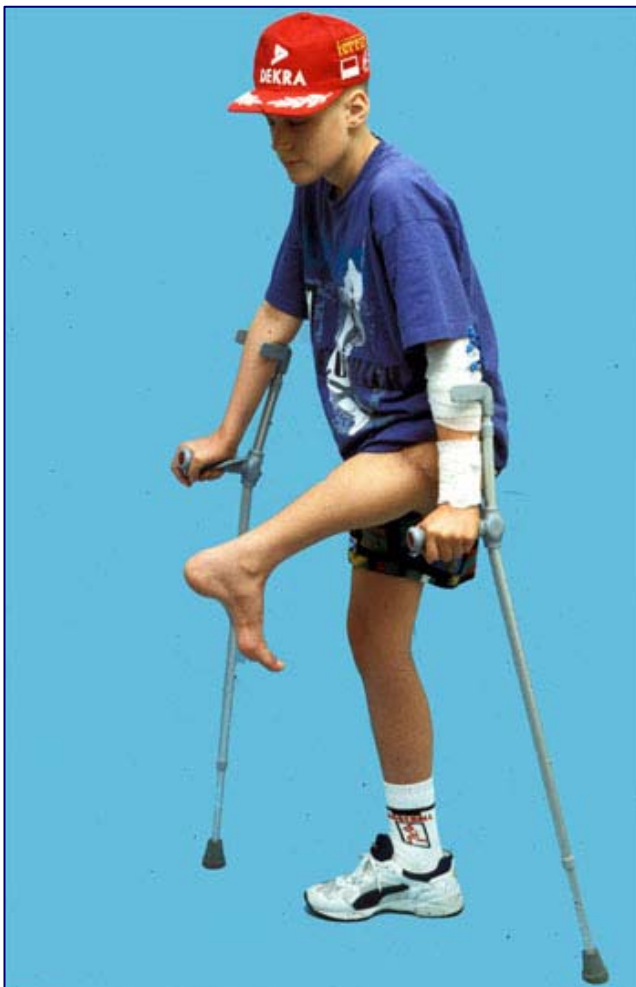ankle joint functions as new knee joint



Surgical treatment of sarcomas




Orthopädie Heidelberg





Surgical treatment of sarcomas



Orthopädie Heidelberg





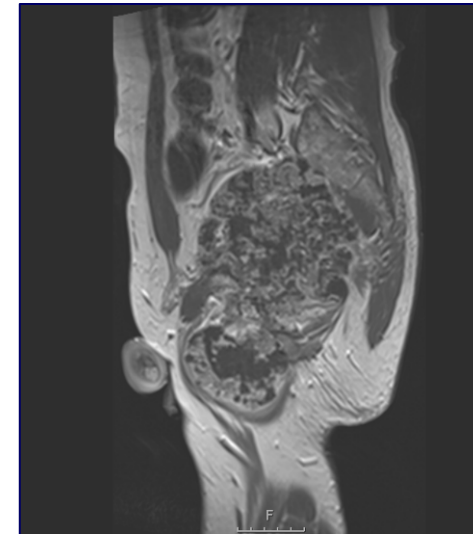
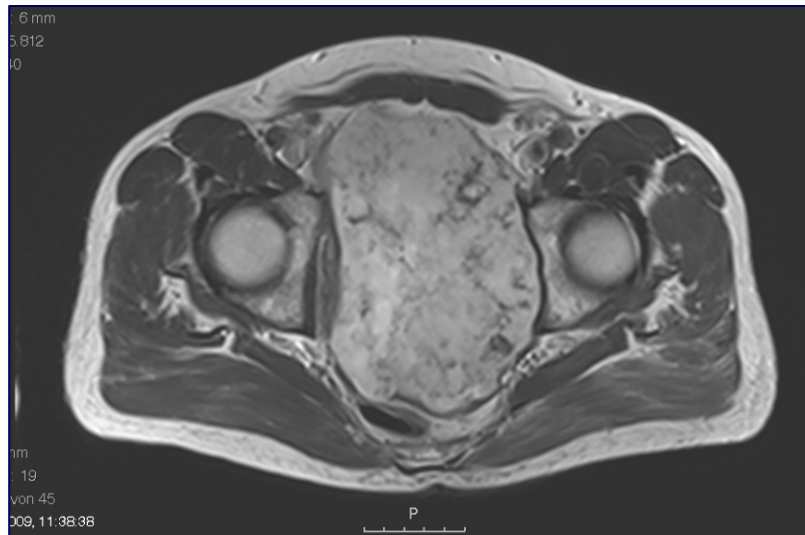
Surgical treatment of sarcomas



Problem cases



Surgical treatment of sarcomas

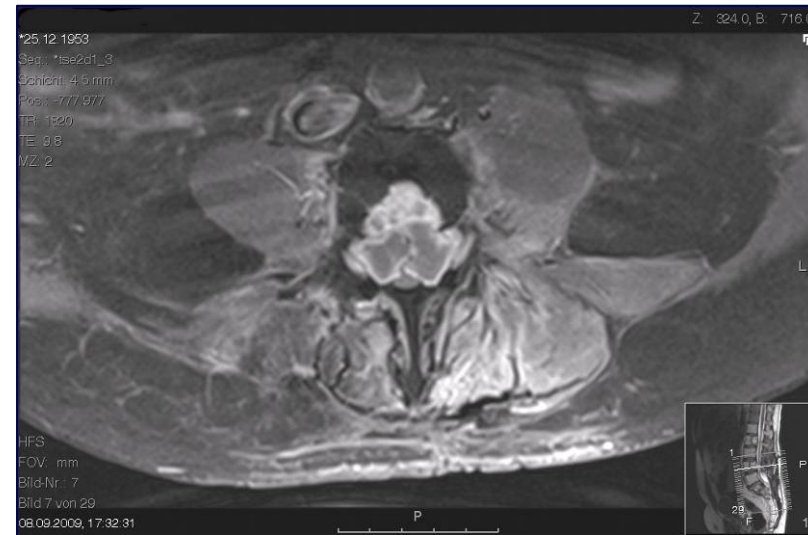
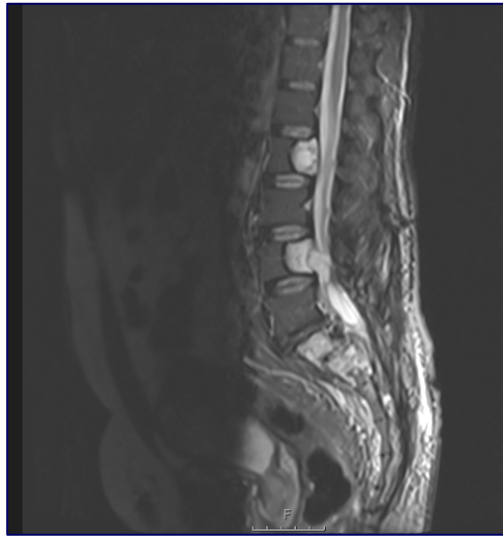


Tumour size

- Chondrosarcoma G II pelvis



Surgical treatment of sarcomas

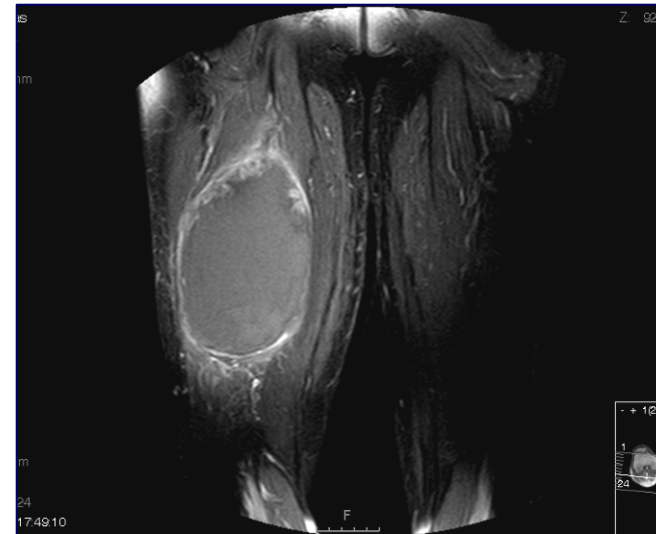
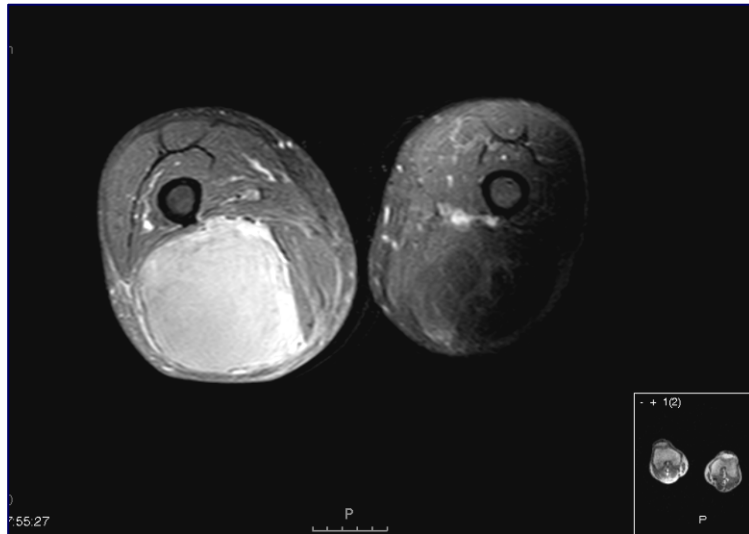


Tumour location

- intraspinal Chondrosarcoma metastasis
- Tumour resection not possible



Surgical treatment of sarcomas

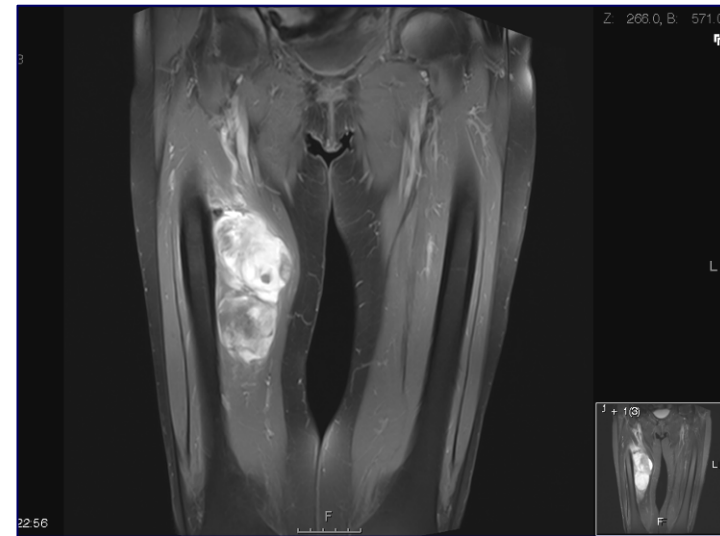
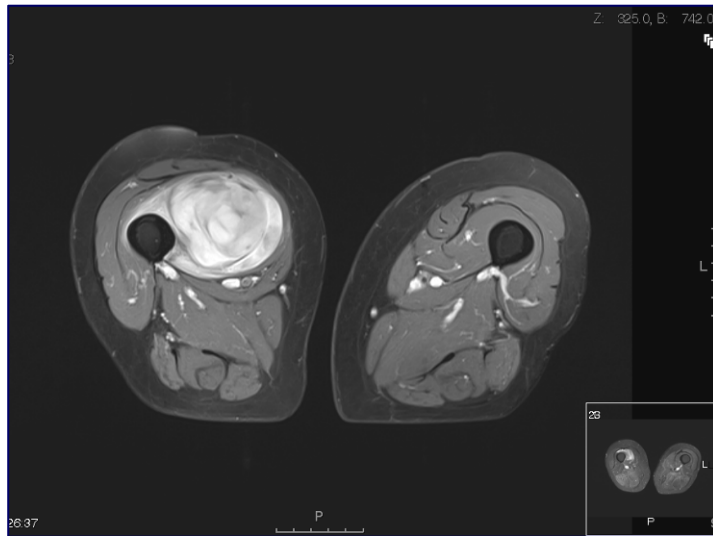


Tumour location

- long segment involvement of vascular and nerv bundle (Rhabdomyosarcoma GIII)



Surgical treatment of sarcomas

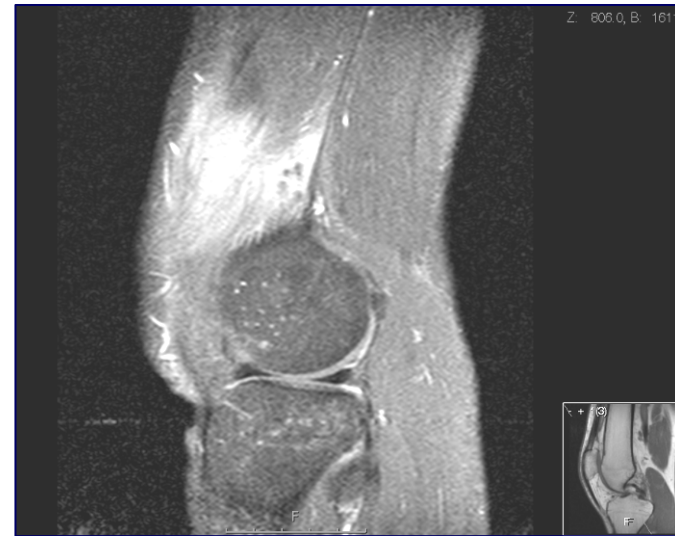
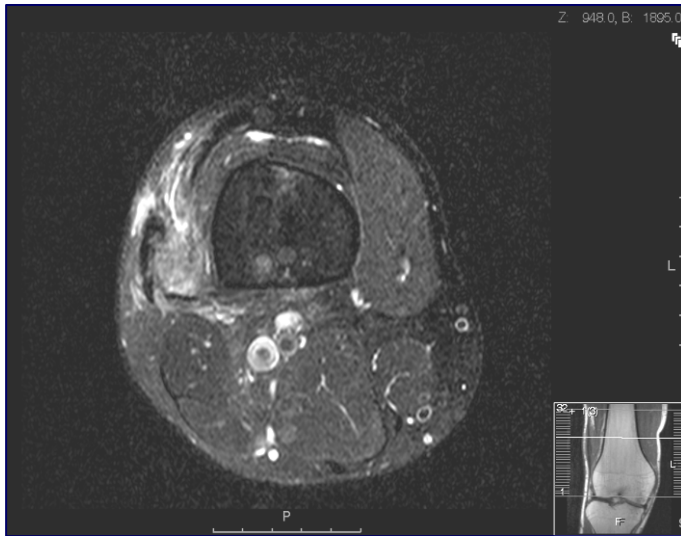
Tumour location

- long segment involvement of bone
(Myxofibrosarcoma GII)



Surgical treatment of sarcomas

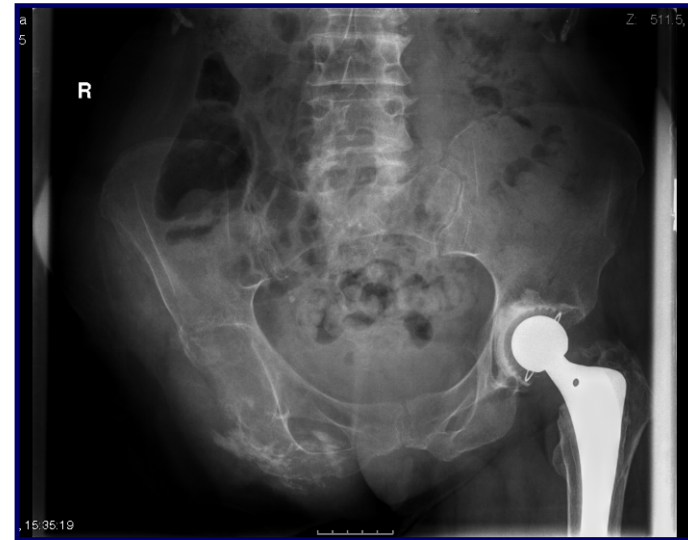
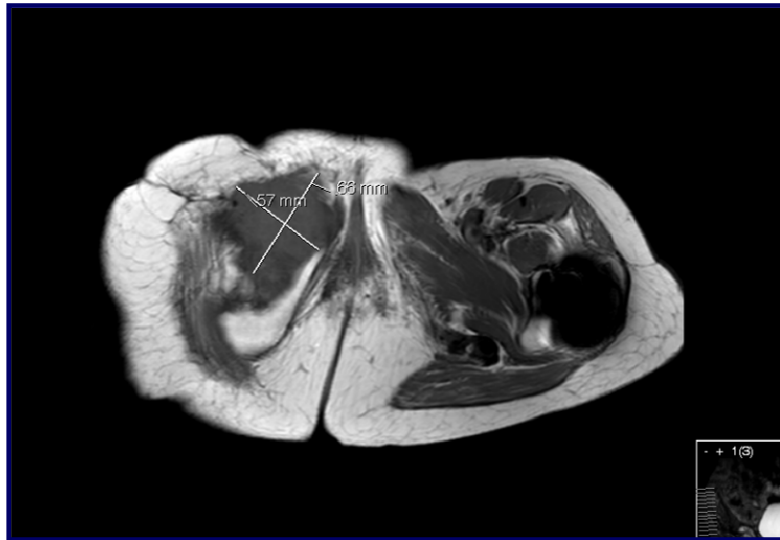


Tumour residuum

- Synovial sarcoma R I resection
- further resection necessary?



Surgical treatment of sarcomas

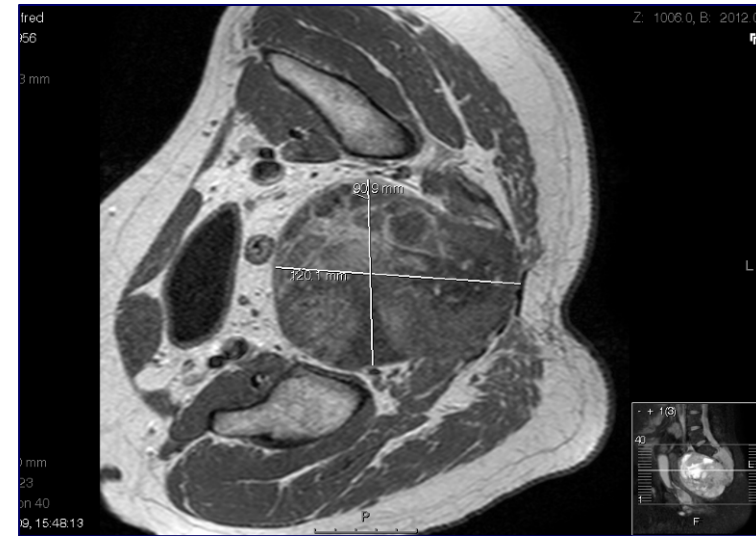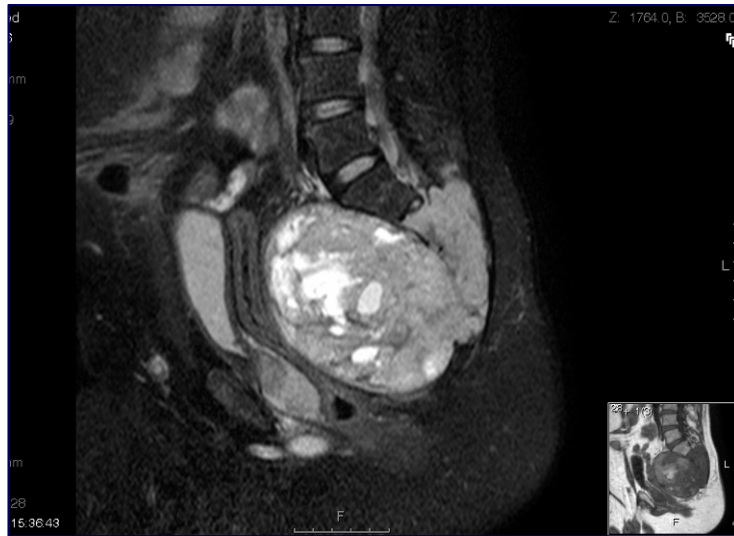


Tumour recurrence

- Spindle cell sarcoma G III left pelvis



Surgical treatment of sarcomas



Tumour entity

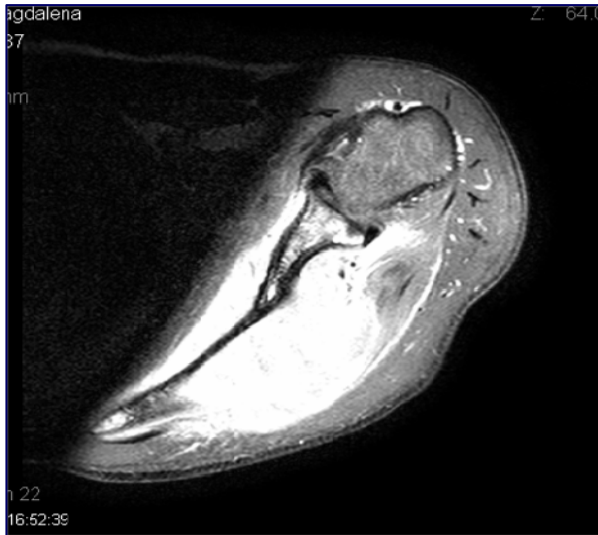- Chordoma with high recurrence rate



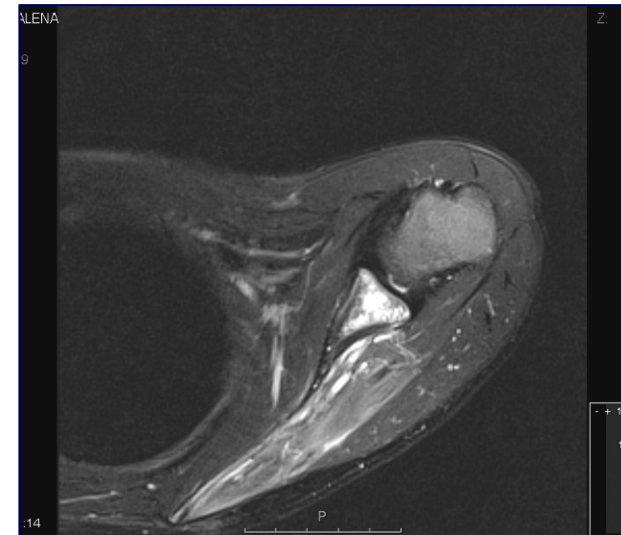
Surgical treatment of sarcomas



Orthopädie Heidelberg



Ewing sarcoma
pre chemotherapy



post chemotherapy

Tumour boundary

- Definition of resection margins after downsizing through neoadjuvant chemotherapy



Surgical treatment of sarcomas



Solution:

Particle therapy ?